

DR LALIMA TIWARI (Orcid ID : 0000-0001-5305-2953)

DR OMAR KUJAN (Orcid ID : 0000-0002-5951-8280)

Article type : Review Article

## **Optical fluorescence imaging in oral cancer and potentially malignant disorders: a systematic review**

Lalima Tiwari<sup>1</sup>, Omar Kujan<sup>1</sup>, Camile S. Farah<sup>2</sup>

<sup>1</sup> UWA Dental School, The University of Western Australia, Nedlands, WA, Australia

<sup>2</sup> Australian Centre for Oral Oncology Research & Education, Nedlands, WA, Australia

\*Corresponding author:

Professor Camile S. Farah

Australian Centre for Oral Oncology Research & Education

Email: [camile@oralmedpath.com.au](mailto:camile@oralmedpath.com.au)

**Keywords:** oral cancer, oral potentially malignant disorders, optical fluorescence imaging, autofluorescence, systematic review

**Running title:** Optical fluorescence imaging in OPMD and OSCC

This article has been accepted for publication and undergone full peer review but has not been through the copyediting, typesetting, pagination and proofreading process, which may lead to differences between this version and the Version of Record. Please cite this article as doi: 10.1111/odi.13071

This article is protected by copyright. All rights reserved.

## Abstract

**Objectives:** This study aimed to systematically review the efficacy of direct optical fluorescence imaging as an adjunct to comprehensive oral examination in the clinical evaluation, risk assessment and surgical management of oral cancer and potentially malignant disorders.

**Methods:** Studies adopting autofluorescence devices, evaluating the efficacy of comprehensive oral examination and optical fluorescence imaging in detection, visualisation or management of oral squamous cell carcinoma or oral potentially malignant disorders, as well as discriminating oral epithelial dysplasia from other mucosal lesions, were included in the literature search across bibliographic databases until October 2018.

**Results:** 28 studies were found to be eligible for inclusion in qualitative analysis. Of these, only six studies demonstrated a low risk of bias across all domains of the methodological assessment tool (QUADAS-2). Optical fluorescence imaging demonstrated positive results, with higher sensitivity scores, increased lesion detection and visualisation than comprehensive oral examination alone in the clinical evaluation of oral squamous cell carcinoma and oral potentially malignant disorders.

**Conclusions:** This review provides promising evidence for the utilisation of optical fluorescence imaging as an adjunct to comprehensive oral examination in varying clinical settings. It is important that devices utilising optical fluorescence imaging are viewed strictly as clinical adjuncts and not specifically as diagnostic devices.

## Background

Oral squamous cell carcinoma (OSCC) is a major health burden responsible for a significant proportion of morbidity and mortality worldwide (Shield et al., 2017). The overall five-year survival rate is around 50% but it can reach as low as 15% depending on the stage of diagnosis (Farah et al., 2014; McCullough, Prasad, & Farah, 2010). Early stage OSCC and oral epithelial dysplasia (OED) often manifest as subtle mucosal changes classified as oral potentially malignant disorders (OPMD) (Epstein, Güneri, Boyacioglu, & Abt, 2012; Speight, Khurram, & Kujan, 2018). Early

detection and effective management of these lesions is crucial for improving survival rates and preventing oral cancer progression (Epstein et al., 2012).

Current practice for detection of OPMD involves a conventional oral examination (COE) with visual and tactile examination under white light (Epstein et al., 2012; Lingen, Kalmar, Karrison, & Speight, 2008). To confirm clinical findings, patients are usually referred to a specialist centre for surgical biopsy of suspicious lesions for definitive diagnosis and management (Epstein et al., 2012; Lingen et al., 2008). The decision to biopsy is currently based on the clinical judgement of the practitioner, which is significantly influenced by the findings from COE. Unfortunately, COE has been shown to be a poor predictor of OSCC and OED, with a sensitivity and specificity of 93% and 31% respectively, consequently introducing limitations to the diagnostic process (Epstein et al., 2012; Lingen et al., 2008; Macey et al., 2015).

As a result, many diagnostic adjuncts have been developed, however these have been utilised and assessed in a manner to replace, rather than complement, COE (Bhatia, Lalla, Vu, & Farah, 2013). Optical fluorescence imaging (OFI) has been extensively scrutinised as a diagnostic adjunct, with many studies outlining poor diagnostic yield for OSCC and OED, or demonstrating inconclusive results due to poor study design and heterogeneity (Lingen, Tampi, et al., 2017; Luo et al., 2016; Macey et al., 2015). Furthermore, there has been much debate with regards to how OFI is utilised in clinical settings. Based on previous systematic reviews, the American Dental Association have recently recommended against the use of autofluorescence imaging for the assessment of clinically evident lesions (Lingen, Abt, et al., 2017). While this comment may hold true if based purely on diagnostic capability of the device, adjunctive OFI has demonstrated use in other aspects of clinical practice providing the practitioner more clinical information, in the form of lesion detection, lesion assessment, and lesion management than information gathered by COE alone (Bhatia et al., 2013). At present, there is no published systematic review assessing OFI in this capacity. This review therefore aimed to provide contemporary evidence on the efficacy of direct OFI as an adjunctive tool to COE in the clinical evaluation, risk assessment and management of OPMD and OSCC.

## Methods

### *Data sources and search strategy*

This systematic review was performed according to the Preferred Reporting Items for Systematic Reviews and Meta-Analysis (PRISMA) (Liberati et al., 2009). Electronic databases Medline, Web of Science, Embase and Scopus were searched until October 2018 using a combination of “MESH terms” outlined in Table S1. In addition, references were hand-checked from bibliographies in relevant articles and included in this review.

### *Selection Process based on PICO model*

The inclusion criteria used in the selection of literature for this review were as follows:

- Randomised, non-randomised control trials, prospective or retrospective cohort and cross-sectional studies in English
- Adopting autofluorescence tools in a general dental or specialist practitioner setting
- Investigating and evaluating the efficacy of both COE and OFI in:
  - detection of OPMD and/or OSCC
  - visualisation of OPMD and/or OSCC
  - discrimination of benign oral lesions from OPMD and/or OSCC
  - detection of OED in OPMDs
  - surgical management of OPMD and/or OSCC
  - long-term surveillance of OPMDs
- Studies had to report efficacy values, or had enough data reported that these could be calculated.

Exclusion criteria:

Studies utilising indirect autofluorescence examinations or algorithms as diagnostic tools were excluded as this form of examination did not meet our objective.

### *Types of participants*

Participants who underwent examination with both conventional oral examination and optical autofluorescence imaging either in a general dental practitioner setting or specialist centre setting.

### *Types of interventions and comparator*

Studies for inclusion had to have a COE comparison to tissue autofluorescence. Studies discriminating benign oral lesions from OPMD and/or OSCC, detecting OED and OSCC, or discussing surgical management of OPMD and/or OSCC with the aid of OFI had to have histopathological confirmation. Studies evaluating autofluorescence imaging in a general dental setting or for long-term surveillance of lesions did not require histopathological confirmation as the oral medicine specialist was considered the gold standard in these scenarios.

### *Types of outcome measures*

#### *Primary Outcomes*

Primary outcome measures for this review focused on evaluating the efficacy of OFI in clinical evaluation, risk assessment or management of OPMD and/or OSCC. These categories were further divided into specific outcome measures (Table S2).

#### *Secondary Outcomes*

Secondary outcomes with regards to the efficacy of OFI as an adjunct to COE in general dental practice and its value in long-term surveillance of OPMDs were also assessed.

## Results

### *Study selection*

A total of 124 studies were screened by title and abstract, with 79 full-text articles assessed for eligibility and only 28 studies meeting the inclusion criteria (Figure 1). For each study, data was extracted using a standardised data collection form and studies were qualitatively assessed using the QUADAS-2 tool (Table S3). Two reviewers (LT and OK) independently evaluated the articles included in the study. Data was extracted and summarised in Tables 1 and 2 based on primary and secondary outcome measures respectively. Of the 28 included studies, six demonstrated a low risk of bias across all QUADAS-2 domains (Bhatia, Matias, & Farah, 2014; Farah, McIntosh, Georgiou, & McCullough, 2012; Lalla, Matias, & Farah, 2015, 2016; Paderni et al., 2011; Rana, Zapf, Kuehle, Gellrich, & Eckardt, 2012).

### ***Efficacy of autofluorescence in clinical evaluation of OPMD and OSCC***

15 studies reported efficacy on detection of OPMD and/or OSCC, with significant heterogeneity and risk of bias noted across the methodologies used. (Awan, Morgan, & Warnakulasuriya, 2011; Betz et al., 2002; Bhatia et al., 2014; Cănjău, Todea, Sinescu, Pricop, & Duma, 2018; Chiang et al., 2018; Farah et al., 2012; Koch, Kaemmerer, Biesterfeld, Kunkel, & Wagner, 2011; Lalla et al., 2016; Marzouki et al., 2012; Moro et al., 2010; Onizawa, Saginoya, Furuya, & Yoshida, 1996; Petruzzi et al., 2014; Sawan & Mashlah, 2015; Scheer et al., 2016; Simonato, Tomo, Miyahara, Navarro, & Villaverde, 2017; Sweeny et al., 2011). Only 3/15 studies demonstrated low risk of bias across all QUADAS-2 domains (Bhatia et al., 2014; Farah et al., 2012; Lalla et al., 2016). Two studies assessed the efficacy of VELscope as an adjunct to COE (Bhatia et al., 2014; Farah et al., 2012). Farah et al. utilised VELscope in the specialist dental setting, evaluating red and white lesions, using histopathology as a gold standard, while Bhatia et al. utilised VELscope in a general dental clinic with a referral to an oral medicine specialist as the gold standard (Bhatia et al., 2014; Farah et al., 2012). Both studies demonstrated higher sensitivity values (Bhatia et al., 2014; Farah et al., 2012). Farah et al. reported a combined sensitivity score of 46% compared to 25% with COE alone (Farah et al., 2012), while Bhatia et

al. reported a combined sensitivity score of 73.9% compared to 44% with COE alone in the detection of OPMD and/or OSCC (Bhatia et al., 2014). A reduction in specificity values was noted in both studies when VELscope was utilised as an adjunct to COE compared to the use of COE alone; with Farah et al. reporting a combined specificity of 68% compared to 82% and Bhatia et al. reporting a combined specificity of 97.1% compared to 99% (Bhatia et al., 2014; Farah et al., 2012). The third, prospective cross-sectional study deemed to have low risk of bias assessed the efficacy of Identafi's multispectral light (Lalla et al., 2016). Identafi's white light demonstrated equivalent accuracy to COE conducted under extra-oral LED white light, while the violet (autofluorescence) light alone, demonstrated low sensitivity and specificity values for the detection of OPMD and/or OSCC based on both clinical outcomes (27.5%, 27.5%) and histopathology (12.5%, 85.4%) (Lalla et al., 2016). The authors however did not report efficacy values for Identafi as an adjunctive tool (Lalla et al., 2016).

#### *Autofluorescence in visualisation of an oral mucosal lesion*

8 studies reported data on visualisation of oral mucosal lesions (Betz et al., 2002; Bhatia et al., 2014; Farah et al., 2012; Jayaprakash et al., 2009; Lalla et al., 2015, 2016; Marzouki et al., 2012; Paderni et al., 2011), with 3/8 studies having a low risk of bias across all QUADAS-2 domains (Bhatia et al., 2014; Farah et al., 2012; Lalla et al., 2016). 6/8 studies reported additional lesion detection with AF compared to COE alone (Betz et al., 2002; Bhatia et al., 2014; Farah et al., 2012; Jayaprakash et al., 2009; Lalla et al., 2016; Marzouki et al., 2012). 3/5 studies reporting border distinctness noted subjectively, greater improvements in border distinctness with AF compared to COE alone (Betz et al., 2002; Bhatia et al., 2014; Lalla et al., 2016). 2/5 studies noted improved visibility (Bhatia et al., 2014; Paderni et al., 2011) while the other 3 did not note any significant difference when compared with LED WL and magnification loupes (Farah et al., 2012; Lalla et al., 2015, 2016).

### *Autofluorescence as an adjunctive tool to COE*

A large range in efficacy values on adjunctive OFI in detecting OPMD/OSCC was noted across 7 studies (Sensitivity: COE alone vs AF as adjunct: 17% - 99.2% vs 73.9% - 100%, Specificity: COE alone vs AF as adjunct: 33.3% - 99% vs 38% - 97.9%) (Table S1) (Amirchaghmaghi et al., 2018; Betz et al., 2002; Bhatia et al., 2014; Farah et al., 2012; Hanken et al., 2013; Jayaprakash et al., 2009; Rana et al., 2012). 3/7 studies were deemed to have a low risk of bias across all QUADAS-2 domains (Bhatia et al., 2014; Farah et al., 2012; Rana et al., 2012). Bhatia et al., Farah et al. and Rana et al., all reported higher sensitivity values when using AF as an adjunctive tool (73.9%, 46%, 100% respectively) compared to COE alone (44%, 25%, 17% respectively), however decreased specificity when compared to COE alone (97.1%, 68%, 74% respectively vs 99%, 82%, 97% respectively) (Bhatia et al., 2014; Farah et al., 2012; Rana et al., 2012).

### ***Efficacy of autofluorescence in the risk assessment of oral mucosal lesion***

#### *Aiding in the decision to biopsy*

No included studies reported data on this parameter.

#### *Discrimination of benign oral lesions from dysplastic or cancerous lesions*

21 studies reported efficacy on optical autofluorescence in discriminating between benign, dysplastic and neoplastic oral lesions (Amirchaghmaghi et al., 2018; Awan, Morgan, & Warnakulasuriya, 2015; Awan et al., 2011; Babiuch, Chomyszyn-Gajewska, & Wszyńska-Pawełec, 2012; Betz et al., 2002; Chiang et al., 2018; Farah et al., 2012; Hanken et al., 2013; Jayaprakash et al., 2009; Koch et al., 2011; Lalla et al., 2016; Marzouki et al., 2012; Mehrotra et al., 2010; Moro et al., 2010; Paderni et al., 2011; Petruzzi et al., 2014; Rana et al., 2012; Scheer et al., 2011; Simonato et al., 2017). Significant heterogeneity and variation in reported efficacy (COE alone: Sensitivity: 5.9% - 96.6%; Specificity: 42.9% - 97.8%, OFI alone: Sensitivity: 30% - 100%; Specificity: 12.5% - 93%, Combined examination:



Sensitivity: 46% - 100%; Specificity: 6% - 74%) were noted. An overall reduction in specificity was noted when OFI was utilised (alone or as an adjunct) compared to COE.

### ***Efficacy of autofluorescence in the management of OPMD and or OSCC***

#### *Efficacy of AF determining surgical margins in excisions of OPMD and or OSCC*

No studies met the inclusion criteria for management of surgical excision margins.

#### ***Secondary Outcomes:***

One study assessed autofluorescence examination as an adjunctive tool to COE in general dental practice (Bhatia et al., 2014). This study was deemed to have a low risk of bias and demonstrated higher sensitivity values with a slight reduction in specificity compared to COE alone in the detection of oral mucosal lesions (73.9%, 97.1% vs 44%, 99%) (Bhatia et al., 2014). No studies reported efficacy of autofluorescence in the long-term surveillance of OPMDs.

### **Discussion**

Of the 28 included studies, six demonstrated a low risk of bias across all QUADAS-2 domains (Table S2) (Bhatia et al., 2014; Farah et al., 2012; Lalla et al., 2015, 2016; Paderni et al., 2011; Rana et al., 2012). Out of these six studies, only 3 studies utilised OFI as an adjunctive tool, demonstrating promising evidence that detection of OPMD and OSCC can be improved in clinical practice with the use of adjunctive OFI (Bhatia et al., 2014; Farah et al., 2012; Rana et al., 2012). Rana et al. was the only study identified to use a randomized control study protocol. The results from this study reported a 100% sensitivity when OFI was used as an adjunct compared to 17% with COE alone (Rana et al., 2012). A similar result was seen by both Farah et al. and Bhatia et al. who reported higher sensitivity scores with adjunctive OFI than COE alone in a specialist and general dental setting respectively using a prospective cross-sectional study design (Bhatia et al., 2014; Farah et al., 2012). All three studies assessed the efficacy of VELscope®, with appropriate autofluorescence

examination techniques as per manufacturer's instructions, defining a positive autofluorescence parameter as loss of fluorescence and negative diascopy (no blanching) as indicative for dysplasia or malignancy (Bhatia et al., 2014; Farah et al., 2012; Rana et al., 2012). Furthermore, Rana et al. and Bhatia et al. also employed a two week review protocol for lesions that were suspicious of acute inflammatory origin or where loss of autofluorescence (LAF) could not be clinically accounted for, in an attempt to reduce the rate of false-positive results, further contributing to their high sensitivity scores (Bhatia et al., 2014; Rana et al., 2012).

Lesion visualisation and clinical appearance are vital to COE for appropriate diagnosis of OPMD and OSCC (Epstein et al., 2012). It has been shown that visualisation of oral mucosal lesions is greatly influenced by the type of light source used to conduct the examination (McIntosh, McCullough, & Farah, 2009). A study by McIntosh et al. noted better visualisation of lesions using white light emitted from a LED headlight compared to standard dental incandescent yellow light during COE (McIntosh et al., 2009). It is interesting to note that in the current review only 10/28 studies utilised white light to conduct COE (Betz et al., 2002; Cănjău et al., 2018; Hanken et al., 2013; Jayaprakash et al., 2009; Lalla et al., 2016; Lane et al., 2006; Paderni et al., 2011; Simonato et al., 2017; Sweeny et al., 2011). Given the pre-existing subjectivity of COE, optimisation of COE through the standardised use of white LED light to conduct COE may enhance visualisation of oral mucosal lesions in COE alone, and in turn aid in improving accuracy of diagnosis of oral mucosal lesions. Furthermore, the results from this review demonstrate the potential added benefit of the use of adjunctive OFI in improving visualisation of oral mucosal lesions. An overall increase in the number of lesions detected were noted with OFI compared to COE alone (Betz et al., 2002; Bhatia et al., 2014; Farah et al., 2012; Jayaprakash et al., 2009; Lalla et al., 2016; Marzouki et al., 2012), in addition to reported subjective improvement in border distinctness (Betz et al., 2002; Bhatia et al., 2014; Lalla et al., 2016). Of these studies, Bhatia et al, Farah et al., and Lalla et al., were deemed to have a low risk of bias. All three studies reported additional lesion detection under OFI, with Bhatia et al., reporting the highest number of additional lesions detected in 61 patients, enhancing lesion detection by 20% and changing the provisional diagnosis in 12.8% of patients (Bhatia et al., 2014; Farah et al., 2012; Lalla et al., 2016). Given these preliminary findings, optimisation of COE

with the use of white LED light, in addition to OFI may improve the current diagnostic process by providing the clinician with enhanced lesion information and consequently contributing to a more accurate diagnosis of OPMD or OSCC.

The detection of OED or discrimination between benign, dysplastic or malignant oral mucosal lesions has been extensively researched, with literature reporting overall poorer specificity along with significant heterogeneity in published studies (Awan & Patil, 2015; Lingen, Tampi, et al., 2017; Luo et al., 2016). The results from this review are in keeping with previous studies assessing discrimination between oral mucosal lesions, demonstrating significant heterogeneity and variation in reported efficacy (COE alone: Sensitivity: 5.9% - 96.6%; Specificity: 42.9% - 97.8%, OFI alone: Sensitivity: 30% - 100%; Specificity: 12.5% - 93%, Combined examination: Sensitivity: 46% - 100%; Specificity: 6% - 74%) (Amirchaghmaghi et al., 2018; Awan et al., 2015, 2011; Babiuch et al., 2012; Betz et al., 2002; Chiang et al., 2018; Farah et al., 2012; Hanken et al., 2013; Jayaprakash et al., 2009; Koch et al., 2011; Lalla et al., 2016; Lane et al., 2006; Marzouki et al., 2012; Mehrotra et al., 2010; Moro et al., 2010; Paderni et al., 2011; Petruzzi et al., 2014; Rana et al., 2012; Sawan & Mashlah, 2015; Scheer et al., 2011; Simonato et al., 2017). It is also interesting to note that all studies with a low risk of bias except Paderni et al., reported an overall reduction in specificity using OFI compared to COE alone and at present OFI cannot replace histopathological assessment of a tissue biopsy as the gold standard for the diagnosis of OED or OSCC (Bhatia et al., 2014; Farah et al., 2012; Lalla et al., 2016; Paderni et al., 2011; Rana et al., 2012). Based on the results of this review though, a significant component of the heterogeneity can be attributed to the inconsistent implementation of autofluorescence examination. Many studies have reported that autofluorescence examination is subjective, requires initial training to gain confidence in its interpretation, and is often considered a limitation of the device (Bhatia et al., 2013; Farah et al., 2012; Lingen, Tampi, et al., 2017; Petruzzi et al., 2014). It is noteworthy however, that none of the included studies assessed subjectivity of the device via an inter-observer agreement method of assessment, making it difficult to reliably comment on the subjectiveness of the examination. Furthermore, inconsistent use of positive autofluorescence parameters were noted throughout the included studies, further adding to the lack of standardised technique and interpretation of autofluorescence findings. Only seven of the included 28

Accepted Article

studies utilised diascopic fluorescence and included a negative diascopy reading coupled with LAF as a positive finding for dysplasia or malignancy (Bhatia et al., 2014; Farah et al., 2012; Lalla et al., 2015, 2016; Paderni et al., 2011; Rana et al., 2012). Diascopy is a technique advised by the manufacturers of these devices to help delineate underlying vascular or inflammatory lesions, and hence differentiate between benign and potentially malignant lesions. Some studies have not supported the use of diascopy due to the perceived lack of evidence available to substantiate its use (Awan et al., 2015, 2011; Mehrotra et al., 2010). A recent study by Kordbacheh et al. however, aimed to elucidate the underlying molecular pathways associated with fluorescence properties found diascopic fluorescence to be strongly associated with inflammatory reactions in oral epithelial hyperplasia and dysplasia, and is a common finding in lesions such as oral lichen planus (Kordbacheh, Bhatia, & Farah, 2016). Further knowledge of underlying fluorescence properties may provide an avenue for standardisation of the use of these devices and in turn aid in improving overall specificity and utility of OFI.

Currently there is no clear evidence of effective treatment of OPMD, although some data suggests a role for surgical management of OED in reducing risk of malignant transformation (Lodi et al., 2016; Mehanna, Rattay, Smith, & McConkey, 2009; Speight et al., 2018). Given that molecular abnormalities or even cellular changes consistent with dysplasia can be present in clinically normal tissue, the current method of excision with a margin of macroscopically normal tissue is not precise and is likely to result in subtle mucosal abnormalities being missed with resultant recurrences or malignant transformation (Farah, Kordbacheh, John, Bennett, & Fox, 2017; Poh et al., 2006). The role of OFI in surgical management of OPMD and OSCC has in fact been reported in the literature, however these studies failed to meet the inclusion criteria of this review (Farah et al., 2018; Poh et al., 2006). This is an inherent limitation of this review, as the inclusion criteria were limited to those studies reporting efficacy of OFI only. There are two studies providing molecular evidence to support the use of OFI in the surgical excision of OPMD and OSCC (Farah et al., 2018; Poh et al., 2006). Poh et al. delineated field changes in autofluorescence around OSCC and compared the histopathologic and molecular changes of margin biopsies that retained normal autofluorescence with those

margins that showed LAF (Poh et al., 2006). Results from that study strongly indicated that LAF within or beyond the clinically apparent tumour area was associated with morphologic high-grade and molecularly high-risk tissue change (Poh et al., 2006). The findings further showed that direct OFI can identify subclinical high-risk fields with cancerous and precancerous changes in the operating room setting and demonstrate a potential for their use in mapping excision margins (Poh et al., 2006). These results were further substantiated by a recent study by Farah et al. that found distinct molecular differences between excision margins of OPMDs determined by white light compared to autofluorescence; in that OFI-determined margins harboured less molecular abnormalities than margins determined by white light, providing strong evidence for the use of OFI in the surgical management of OPMD (Farah et al., 2018).

Finally, the use of OFI in a general dental setting has not been encouraged (Lingen, Tampi, et al., 2017), however a study conducted by Bhatia et al., with a low risk of bias reported the usefulness of OFI as an adjunctive tool to COE in general dental practice with sensitivity and specificity scores of 73.9% and 97.9% compared to 44.0% and 99.0% with COE alone utilising a decision making protocol and a two week reassessment of lesions demonstrating LAF (Bhatia et al., 2014). This finding is in keeping with a study published by Laronde et al. that noted a 2.7-fold increased risk of intermediate and high-risk lesions demonstrating persistent LAF at the review appointment compared to retained fluorescence (Laronde et al., 2014). This latter study was not eligible for inclusion in the systematic review due to a lack of reported efficacy values. Both studies however demonstrate the promise for adjunctive OFI examination in the general dental setting, by utilising a decision-making protocol for lesion risk assessment (Bhatia et al., 2014; Laronde et al., 2014).

#### *Future direction and minimizing risk of bias*

Only six of the 28 included studies showed a low-risk of bias that have demonstrated promising results for the role of adjunctive OFI to COE in varying aspects of clinical practice. By enhancing the level of clinical information attained through lesion detection or visualisation, and achieving clearer surgical margins of OPMD and

OSCC, OFI can play an important role in improving overall patient management. Despite this, many published studies are of poor quality and therefore future prospective, controlled studies are still required in these areas of clinical practice to build on current evidence supporting the use of these devices. Future studies should avoid the major methodological errors that have been noted in many of the included studies in this review. These include unsatisfactory discussion of patient inclusion and exclusion criteria (Cânjău et al., 2018; Marzouki et al., 2012; Petruzzi et al., 2014; Sawan & Mashlah, 2015; Sweeny et al., 2011), small sample size (Babiuch et al., 2012; Cânjău et al., 2018; Marzouki et al., 2012; Moro et al., 2010; Onizawa et al., 1996; Scheer et al., 2016; Simonato et al., 2017; Sweeny et al., 2011) and insufficient reporting of patient characteristics (Babiuch et al., 2012; Jayaprakash et al., 2009; Marzouki et al., 2012; Moro et al., 2010; Petruzzi et al., 2014). Studies including patients with a history of treated oral cancer should provide clear details of their treatment history, as it has been shown that evaluation of oral soft tissues is challenging with OFI in patients who have undergone oral cancer treatment, especially radiotherapy (Hancock, Epstein, & Sadler, 2003). Studies failing to do this contribute to an unclear or high risk of bias in interpretation of autofluorescence results (Babiuch et al., 2012; Jayaprakash et al., 2009; Marzouki et al., 2012; Moro et al., 2010). Furthermore, future studies should include assessment of subjectivity of autofluorescence examination via an inter-observer agreement assessment. This review also noted that many studies assessed the role of OFI devices as a stand-alone diagnostic tool, rather than a true adjunctive device (Awan et al., 2015, 2011; Babiuch et al., 2012; Cânjău et al., 2018; Chiang et al., 2018; Mehrotra et al., 2010; Moro et al., 2010; Onizawa et al., 1996; Paderni et al., 2011; Petruzzi et al., 2014; Sawan & Mashlah, 2015; Scheer et al., 2016, 2011). Given the potential promising role of OFI in various clinical settings, it is recommended that this technology be considered as a “clinical” adjunct, instead of a “diagnostic” adjunct. Perhaps changing our perspective on the use of these devices may encourage users to redirect their studies from investigating its ability to replace COE, to using it in practice as a complementary tool to COE, as it is intended.

Finally, the importance of standardising the use of OFI cannot be emphasized enough to minimise the risk of bias in future studies and improve accuracy scores of these devices. Based on current evidence with minimal bias, we advise that future

Accepted Article  
studies undertake standardised use of white LED light to conduct COE, utilise diascopy as a standard part of the autofluorescence examination, standardise the autofluorescence parameters to include LAF with negative diascopy as indicative for dysplasia or malignancy, indicate partial vs complete diascopy, incorporate a two week review protocol, and report efficacy data for COE alone, OFI alone and as a combined examination to provide reliable results and contribute towards meaningful meta-analyses in the future.

### **Conclusions**

The results of this review demonstrate promising evidence for the use adjunctive OFI to COE in varying aspects of clinical practice, contributing to the overall improvement in patient management. We suggest a change in perspective concerning this tool; that it be regarded as a clinical adjunct rather than specifically a diagnostic adjunct. This review has highlighted the significant lack of standardisation of the use of OFI devices with regards to technique and interpretation of findings. As a means to improve overall accuracy of these devices, as well as to provide future meaningful data for meta-analyses, standardisation of the use of these devices is of great importance.

### **Conflict of interest declaration**

Author CSF is senior or lead author on several papers highlighted in this systematic review. He has undertaken multiple laboratory and clinical research projects on optical fluorescence imaging but declares no conflict of interest in relation to any of the devices named in this review or affiliation with their respective manufacturer.

## References

- Amirchaghmaghi, M., Mohtasham, N., Delavarian, Z., Shakeri, M. T., Hatami, M., & Mosannen Mozafari, P. (2018). The diagnostic value of the native fluorescence visualization device for early detection of premalignant/malignant lesions of the oral cavity. *Photodiagnosis and Photodynamic Therapy*, *21*, 19–27. <https://doi.org/10.1016/j.pdpdt.2017.10.019>
- Awan, K., Morgan, P.R., & Warnakulasuriya, S. (2015). Assessing the accuracy of autofluorescence, chemiluminescence and toluidine blue as diagnostic tools for oral potentially malignant disorders-a clinicopathological evaluation. *Clinical Oral Investigations*, *19*(9), 2267–2272. <https://doi.org/10.1007/s00784-015-1457-9>
- Awan, K., Morgan, P. R., & Warnakulasuriya, S. (2011). Evaluation of an autofluorescence based imaging system (VELscope™) in the detection of oral potentially malignant disorders and benign keratoses. *Oral Oncology*, *47*(4), 274–277. <https://doi.org/10.1016/j.oraloncology.2011.02.001>
- Awan, K.H., & Patil, S. (2015). Efficacy of autofluorescence imaging as an adjunctive technique for examination and detection of oral potentially malignant disorders: A systematic Review. *The Journal of Contemporary Dental Practice*, *16*(9), 744–749.
- Babiuch, K., Chomyszyn-Gajewska, M., & Wyszynska-Pawelec, G. (2012). The use of VELscope® for detection of oral potentially malignant disorders and cancers – a pilot study. *Medical and Biological Sciences*, *26*(4), 11–16. <https://doi.org/10.12775/v10251-012-0069-8>
- Betz, C. S., Stepp, H., Janda, P., Arbogast, S., Grevers, G., Baumgartner, R., & Leunig, A. (2002). A comparative study of normal inspection, autofluorescence and 5-ALA-induced PPIX fluorescence for oral cancer diagnosis. *International Journal of Cancer*, *97*(2), 245–252. <https://doi.org/10.1002/ijc.1596>



- Bhatia, N., Lalla, Y., Vu, A. N., & Farah, C. S. (2013). Advances in optical adjunctive aids for visualisation and detection of oral malignant and potentially malignant lesions. *International Journal of Dentistry*, 2013. <https://doi.org/10.1155/2013/194029>
- Bhatia, N., Matias, M. A. T., & Farah, C. S. (2014). Assessment of a decision making protocol to improve the efficacy of VELscope™ in general dental practice: a prospective evaluation. *Oral Oncology*, 50(10), 1012–1019. <https://doi.org/10.1016/j.oraloncology.2014.07.002>
- Cânjău, S., Todea, D. C. M., Sinescu, C., Pricop, M. O., & Duma, V. F. (2018). Fluorescence influence on screening decisions for oral malignant lesions. *Romanian Journal of Morphology and Embryology*, 59(1), 203–209.
- Chiang, T.-E., Lin, Y.-C., Li, Y.-H., Wu, C.-T., Kuo, C.-S., & Chen, Y.-W. (2018). Comparative evaluation of autofluorescence imaging and histopathological investigation for oral potentially malignant disorders in Taiwan. *Clinical Oral Investigations*. Advance online publication. <https://doi.org/10.1007/s00784-018-2691-8>
- Epstein, J. B., Güneri, P., Boyacioglu, H., & Abt, E. (2012). The limitations of the clinical oral examination in detecting dysplastic oral lesions and oral squamous cell carcinoma. *Journal of the American Dental Association*, 143(12), 1332–1342.
- Farah, C.S., Kordbacheh, F., John, K., Bennett, N., & Fox, S.A. (2018). Molecular classification of autofluorescence excision margins in oral potentially malignant disorders. *Oral Diseases*, 24(5), 732–740. <https://doi.org/10.1111/odi.12818>
- Farah, C.S., McIntosh, L., Georgiou, A., & McCullough, M. J. (2012). Efficacy of tissue autofluorescence imaging (VELScope) in the visualization of oral mucosal lesions. *Head & Neck*, 34(6), 856–862. <https://doi.org/10.1002/hed.21834>
- Farah, C.S., Woo, S., Zain, R. B., Sklavounou, A., McCullough, M. J., & Lingen, M. (2014). Oral Cancer and Oral Potentially Malignant Disorders. *International Journal of Dentistry*, 2014. <https://doi.org/10.1155/2014/853479>

Hancock, P. J., Epstein, J. B., & Sadler, G. R. (2003). Oral and dental management related to radiation therapy for head and neck cancer. *Journal of the Canadian Dental Association*, 69(9), 585–590.

Hanken, H., Kraatz, J., Smeets, R., Heiland, M., Blessmann, M., Eichhorn, W., ... Rana, M. (2013). The detection of oral pre-malignant lesions with an autofluorescence based imaging system (VELscope™) – a single blinded clinical evaluation. *Head & Face Medicine*, 9 (23).  
<https://doi.org/10.1186/1746-160X-9-23>

Jayaprakash, V., Sullivan, M., Merzianu, M., Rigual, N. R., Loree, T. R., Popat, S. R., ... Reid, M. E. (2009). Autofluorescence-Guided surveillance for oral cancer. *Cancer Prevention Research*, 2(11), 966–974. <https://doi.org/10.1158/1940-6207.CAPR-09-0062>

Koch, F., Kaemmerer, P., Biesterfeld, S., Kunkel, M., & Wagner, W. (2011). Effectiveness of autofluorescence to identify suspicious oral lesions-a prospective, blinded clinical trial. *Clinical Oral Investigations*, 15(6), 975–982. <https://doi.org/10.1007/s00784-010-0455-1>

Kordbacheh, F., Bhatia, N., & Farah, C. S. (2016). Patterns of differentially expressed genes in oral mucosal lesions visualised under autofluorescence (VELscope™). *Oral Diseases*, 22(4), 285–296. <https://doi.org/10.1111/odi.12438>

Lalla, Y., Matias, M. A. T., & Farah, C.S. (2015). Oral mucosal disease in an Australian urban Indigenous community using autofluorescence imaging and reflectance spectroscopy. *Australian Dental Journal*, 60(2), 216–224. <https://doi.org/10.1111/adj.12320>

Lalla, Y., Matias, M. A. T., & Farah, C. S. (2016). Assessment of oral mucosal lesions with autofluorescence imaging and reflectance spectroscopy. *The Journal of the American Dental Association*, 147(8), 650–660. <https://doi.org/10.1016/j.adaj.2016.03.013>

Lane, P. M., Gilhuly, T., Whitehead, P. D., Zeng, H., Poh, C., Ng, S., ... MacAulay, C. E. (2006). Simple device for the direct visualization of oral-cavity tissue fluorescence. *Journal of Biomedical Optics*, 11(2), 024006. <https://doi.org/10.1117/1.2193157>

Laronde, D. M., Williams, P. M., Hislop, T. G., Poh, C., Ng, S., Bajdik, C., ... Rosin, M. P. (2014).

Influence of fluorescence on screening decisions for oral mucosal lesions in community dental practices. *Journal of Oral Pathology & Medicine*, 43(1), 7–13.

<https://doi.org/10.1111/jop.12090>

Liberati, A., Altman, D. G., Tetzlaff, J., Mulrow, C., Gøtzsche, P. C., Ioannidis, J. P., ... Moher, D. (2009).

The PRISMA statement for reporting systematic reviews and meta-analyses of studies that evaluate healthcare interventions: explanation and elaboration. *BMJ (Clinical Research Ed.)*,

339. <https://doi.org/10.1136/bmj.b2700>

Lingen, M. W., Abt, E., Agrawal, N., Chaturvedi, A. K., Cohen, E., D'Souza, G., ... Carrasco-Labra, A.

(2017). Evidence-based clinical practice guideline for the evaluation of potentially malignant disorders in the oral cavity. *The Journal of the American Dental Association*, 148(10), 712-

727.e10. <https://doi.org/10.1016/j.adaj.2017.07.032>

Lingen, M. W., Kalmar, J. R., Karrison, T., & Speight, P. M. (2008). Critical evaluation of diagnostic aids

for the detection of oral cancer. *Oral Oncology*, 44(1), 10–22.

<https://doi.org/10.1016/j.oraloncology.2007.06.011>

Lingen, M. W., Tampi, M. P., Urquhart, O., Abt, E., Agrawal, N., Chaturvedi, A. K., ... Carrasco-Labra,

A. (2017). Adjuncts for the evaluation of potentially malignant disorders in the oral cavity:

Diagnostic test accuracy systematic review and meta-analysis—a report of the American

Dental Association. *The Journal of the American Dental Association*, 148(11), 797-813.e52.

<https://doi.org/10.1016/j.adaj.2017.08.045>

Lodi, G., Warnakulasuriya, S., Varoni, E., Sardella, A., Kerr, A., Carassi, A., ... Worthington, H. (2016).

Interventions for treating oral leukoplakia to prevent oral cancer. *Cochrane Database of*

*Systematic Reviews*, (7). <https://doi.org/DOI: 10.1002/14651858.CD001829.pub4>

Luo, X., Xu, H., He, M., Han, Q., Wang, H., Sun, C., ... Chen, Q. (2016). Accuracy of autofluorescence in

diagnosing oral squamous cell carcinoma and oral potentially malignant disorders: a

comparative study with aero-digestive lesions. *Scientific Reports*, 6, 29943.

<https://doi.org/10.1038/srep29943>

Macey, R., Walsh, T., Brocklehurst, P., Kerr, A. R., Liu, J. L. Y., Lingen, M. W., ... Scully, C. (2015).

Diagnostic tests for oral cancer and potentially malignant disorders in patients presenting with clinically evident lesions. *The Cochrane Database of Systematic Reviews*, (5), CD010276.

<https://doi.org/10.1002/14651858.CD010276.pub2>

Marzouki, H. Z., Tuong Vi Vu, T., Ywakim, R., Chauvin, P., Hanley, J., & Kost, K. M. (2012). Use of

fluorescent light in detecting malignant and premalignant lesions in the oral cavity: a prospective, single-blind study. *Journal of Otolaryngology - Head & Neck Surgery*, 41(3), 164–168.

McCullough, M., Prasad, G., & Farah, C.S. (2010). Oral mucosal malignancy and potentially malignant

lesions: an update on the epidemiology, risk factors, diagnosis and management. *Australian Dental Journal*, 55, 61–65. <https://doi.org/10.1111/j.1834-7819.2010.01200.x>

McIntosh, L., McCullough, M. J., & Farah, C. S. (2009). The assessment of diffused light illumination

and acetic acid rinse (Microlux/DL™) in the visualisation of oral mucosal lesions. *Oral Oncology*, 45(12), e227–e231. <https://doi.org/10.1016/j.oraloncology.2009.08.001>

McNamara, K. K., Martin, B.D., Evans, E.W., & Kalmar, J. R. (2012). The role of direct visual

fluorescent examination (VELscope) in routine screening for potentially malignant oral mucosal lesions. *Oral Surgery, Oral Medicine, Oral Pathology and Oral Radiology*, 114 (5), 636–643.

Mehanna, H. M., Rattay, T., Smith, J., & McConkey, C. C. (2009). Treatment and follow-up of oral

dysplasia - a systematic review and meta-analysis. *Head & Neck*, 31(12), 1600–1609.

<https://doi.org/10.1002/hed.21131>

Mehrotra, R., Singh, M., Thomas, S., Nair, P., Pandya, S., Nigam, N. S., & Shukla, P. (2010). A cross-

sectional study evaluating chemiluminescence and autofluorescence in the detection of

clinically innocuous precancerous and cancerous oral lesions. *The Journal of the American Dental Association*, 141(2), 151–156. <https://doi.org/10.14219/jada.archive.2010.0132>

Moro, A., Nardo, F. D., Boniello, R., Marianetti, T. M., Cervelli, D., Gasparini, G., & Pelo, S. (2010).

Autofluorescence and early detection of mucosal lesions in patients at risk for oral cancer. *Journal of Craniofacial Surgery*, 21(6), 1899–1903.

<https://doi.org/10.1097/SCS.0b013e3181f4afb4>

Onizawa, K., Saginoya, H., Furuya, Y., & Yoshida, H. (1996). Fluorescence photography as a diagnostic method for oral cancer. *Cancer Letters*, 108(1), 61–66. [https://doi.org/10.1016/S0304-3835\(96\)04388-1](https://doi.org/10.1016/S0304-3835(96)04388-1)

Paderni, C., Compilato, D., Carinci, F., Nardi, G., Rodolico, V., Lo Muzio, L., ... Campisi, G. (2011).

Direct visualization of oral-cavity tissue fluorescence as novel aid for early oral cancer diagnosis and potentially malignant disorders monitoring. *International Journal of Immunopathology and Pharmacology*, 24(2\_suppl), 121–128.

<https://doi.org/10.1177/03946320110240S221>

Petruzzi, M., Lucchese, A., Nardi, G. M., Lauritano, D., Favia, G., Serpico, R., & Grassi, F. R. (2014).

Evaluation of autofluorescence and toluidine blue in the differentiation of oral dysplastic and neoplastic lesions from non dysplastic and neoplastic lesions: a cross-sectional study. *Journal of Biomedical Optics*, 19(7), 076003. <https://doi.org/10.1117/1.JBO.19.7.076003>

Poh, C. F., Zhang, L., Anderson, D. W., Durham, J. S., Williams, P. M., Priddy, R. W., ... Rosin, M. P.

(2006). Fluorescence visualization detection of field alterations in tumor margins of oral cancer patients. *Clinical Cancer Research*, 12(22), 6716–6722. <https://doi.org/10.1158/1078-0432.CCR-06-1317>

Rana, M., Zapf, A., Kuehle, M., Gellrich, N.-C., & Eckardt, A. M. (2012). Clinical evaluation of an

autofluorescence diagnostic device for oral cancer detection: a prospective randomized diagnostic study. *European Journal of Cancer Prevention*, 21(5), 460–466.

<https://doi.org/10.1097/CEJ.0b013e32834fdb6d>

Sawan, D., & Mashlah, A. (2015). Evaluation of premalignant and malignant lesions by fluorescent light (VELscope), *Journal of International Society of Preventive and Community Dentistry*, 5(3), 248–24.

Scheer, M., Fuss, J., Derman, M., Kreppel, M., Neugebauer, J., Rothamel, D., ... Zoeller, J. (2016). Autofluorescence imaging in recurrent oral squamous cell carcinoma. *Oral & Maxillofacial Surgery*, 20(1), 27–33. <https://doi.org/10.1007/s10006-015-0520-7>

Scheer, M., Neugebauer, J., Derman, A., Fuss, J., Drebber, U., & Zoeller, J. E. (2011). Autofluorescence imaging of potentially malignant mucosa lesions. *Oral Surgery, Oral Medicine, Oral Pathology, Oral Radiology, and Endodontology*, 111(5), 568–577. <https://doi.org/10.1016/j.tripleo.2010.12.010>

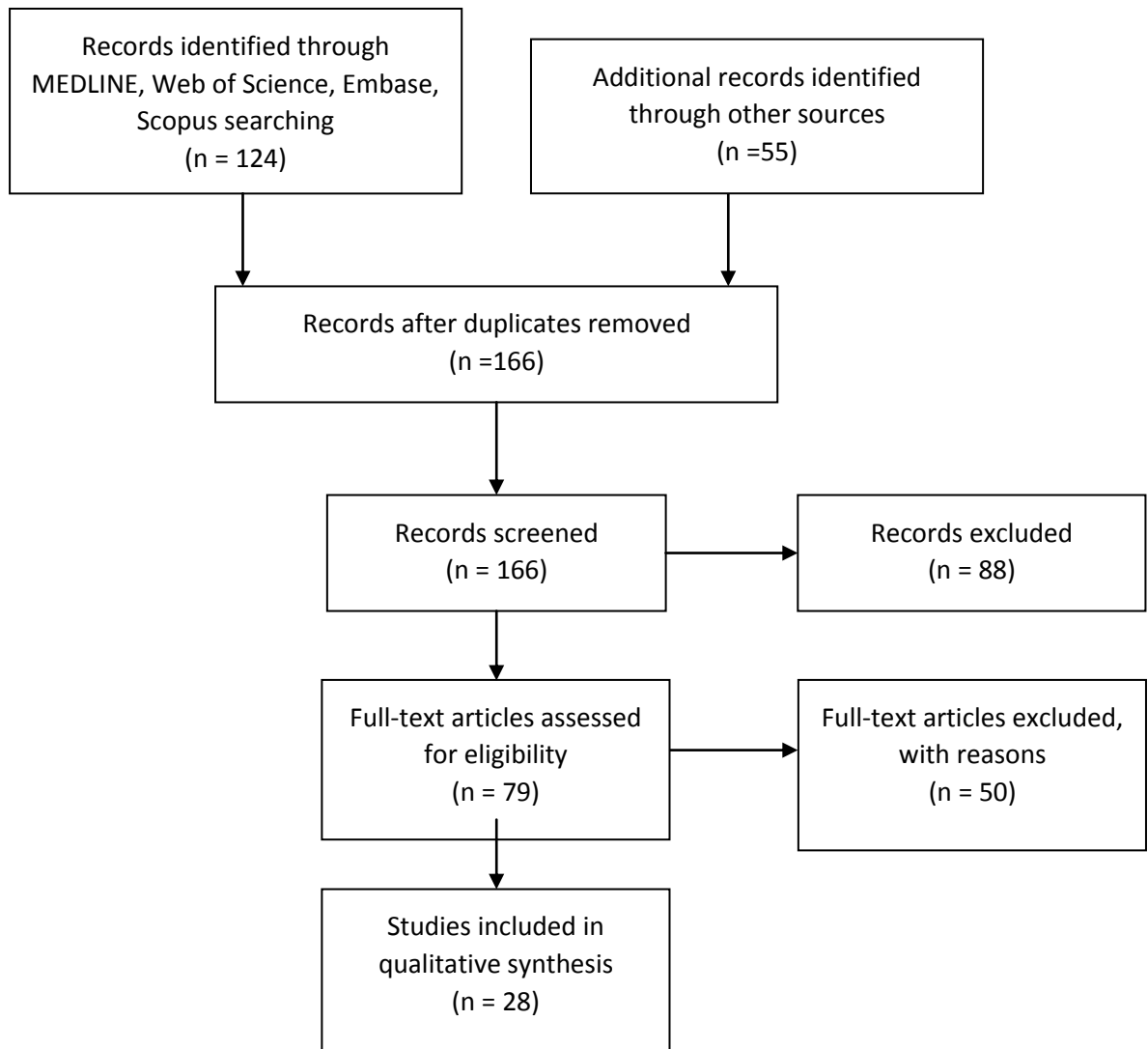
Shield, K. D., Ferlay, J., Jemal, A., Sankaranarayanan, R., Chaturvedi, A. K., Bray, F., & Soerjomataram, I. (2017). The global incidence of lip, oral cavity, and pharyngeal cancers by subsite in 2012. *CA: A Cancer Journal for Clinicians*, 67(1), 51–64. <https://doi.org/10.3322/caac.21384>

Simonato, L. E., Tomo, S., Miyahara, G. I., Navarro, R. S., & Villaverde, A. G. J. B. (2017). Fluorescence visualization efficacy for detecting oral lesions more prone to be dysplastic and potentially malignant disorders: a pilot study. *Photodiagnosis and Photodynamic Therapy*, 17, 1–4. <https://doi.org/10.1016/j.pdpdt.2016.10.010>

Speight, P. M., Khurram, S. A., & Kujan, O. (2018). Oral potentially malignant disorders: risk of progression to malignancy. *Oral Surgery, Oral Medicine, Oral Pathology and Oral Radiology*, 125(6), 612–627. <https://doi.org/10.1016/j.oooo.2017.12.011>

Sweeny, L., Dean, N. R., Magnuson, J. S., Carroll, W. R., Clemons, L., & Rosenthal, E. L. (2011). Assessment of tissue autofluorescence and reflectance for oral cavity cancer screening. *Otolaryngology–Head and Neck Surgery*, 145(6), 956–960. <https://doi.org/10.1177/0194599811416773>

Figure 1: PRISMA flow diagram of screened studies



**Table 1: Efficacy of autofluorescence imaging in detection of OPMD and/or OSCC, as an adjunctive tool to COE and discriminating the presence of dysplasia or neoplasia from other mucosal lesions**

No	Author, Publication Year	General or Specialist Setting	Sample Size	Population Type Assessed	Was COE done prior to AF?	Was WL used	AF device and technique	Use of diascopy	Was there histopathological confirmation of dysplasia or carcinoma	Positive outcome measure	Sensitivity (%)	Specificity (%)
1	Scheer et al. 2016 (Scheer et al., 2016)	Specialist oral surgery	41	Post-treatment OC patients with undiagnosed mucosal lesions	Yes	Not specified	VELscope. Fluorescence characteristics based on photographs. LAF indicates dysplasia or carcinoma	No	Yes	Histopathological confirmation of carcinoma	AF alone: 33.3	AF alone: 88.6
2	Bhatia et al. 2014 (Bhatia et al., 2014)	General dental practice	222	Patients presenting to a general dental clinic for general check-up	Yes	No. Incandescent operatory light	VELscope. LAF or negative diascopy considered positive for dysplasia/SCC. 2 week review protocol used for positive diascopy	Yes	Yes	1. A referral decision to oral medicine specialist 2. Histopathological diagnosis of biopsied lesions	COE alone: 44 AF alone: 64 Combined: 73.9	COE alone: 99 AF alone: 54.3 Combined: 97.9
3	Betz et al. 2002 (Betz et al., 2002)	Specialist otolaryngology	214	Patients with proven malignancy or clinically suspicious lesions of the oral cavity or oropharynx	Yes	Yes	Modified short xenon lamp for in vivo tissue excitation. Subjective darker shade of green was considered positive for malignancy.	Unclear	Yes	Histopathological confirmation of carcinoma only	COE: 99.2 AF alone: 87.8 Combined: 100	COE: 42.9, AF alone: 56.4 Combined: 51.3
4	Koch et al. 2011 (Koch et al., 2011)	Specialist oral surgery	78	Patients with clinically diagnosed SCC or suspicious mucosal lesions	Yes	Yes. Diagnosis based on photographs	VELscope. AF determined from photographs. Low, absent or red AF signal considered positive for dysplasia/SCC.	Unclear	Yes	Histopathological confirmation of carcinoma only	COE: 96.6 AF alone: LAF parameter only: 93 Red AF only: 20	COE: 95.8 AF alone: LAF parameter only: 15 Red AF only: 98
5	Farah et al. 2012 (C.S Farah et al., 2012)	Specialist oral medicine clinic	118	Patients with an oral mucosal lesion (white, mixed white-red).	Yes	No. Incandescent operatory light	VELscope. LAF and negative diascopy was considered indicative for dysplasia/SCC	Yes	Yes	Histopathological diagnosis for dysplasia on histopathology	COE: 25 AF alone: 30 Combined: 46	COE: 82 AF alone: 63 Combined: 68
6	Sawan et al. 2015 (Sawan & Mashlah, 2015)	Specialist centre	71	No inclusion or exclusion criteria	Unclear	Unclear	VELscope. AF parameters not defined	No	Yes	Histopathological diagnosis of carcinoma only	AF alone: 100	AF alone: 74.14

OFI in detection of OPMD and/or OSCC



7	Petruzzi et al. 2014 (Petruzzi et al., 2014).	Specialist oral medicine clinic	56	Patients presenting with oral lesions suspicious for SCC, with history of oral lesions or at high risk for an oral lesion.	Yes	No. Incandescent operatory light.	VELscope. LAF was considered positive for dysplasia or malignancy	No	Yes	Histopathological diagnosis of dysplasia or carcinoma.	AF alone: detection of dysplasia + malignancy: 70 AF alone: detection of moderate/severe OED/SCC (mild dysplasia considered negative): 76.47	AF alone: detection of dysplasia + malignancy: 57.69 AF alone: detection of moderate/severe OED/SCC (mild dysplasia considered negative): 51.28
8	Onizawa et al. 1996 (Onizawa et al., 1996)	Specialist oral surgery clinic	32	Patients with oral mucosal lesions.	Yes	Unclear	Autofluorescence photography. Orange fluorescence was considered positive for malignancy.	No	Yes	Histopathological confirmation of carcinoma only	AF alone: 88	AF alone: 94
9	Marzouki et al. 2012 (Marzouki et al., 2012)	Specialist head and neck oncology clinic	33	Patients with smoking and alcohol history, suspicious lesions, or history of treated oral cancer	Yes	Unclear	VELscope. LAF was deemed positive for dysplasia or carcinoma	No	Yes	Histopathological confirmation of dysplasia or carcinoma	COE: 61.5 AF alone: 92	COE: 87.5 AF alone: 77
10	Moro et al. 2010 (Moro et al., 2010)	Specialist oral medicine clinic	32	Patients with a history of oral cancer, presence of OPMD or suspicious lesion.	Yes	Unclear	Prototype. LED lamp emitting 450nm. No defined parameters	No	Yes	Histopathological confirmation of dysplasia or carcinoma	AF alone: 100	AF alone: 93
11	Sweeny et al. 2011 (Sweeny et al., 2011)	Specialist oral medicine clinic	17	Patients with history of treated head and neck cancer	Yes	Yes	Identafi 3000 ultra. AF parameters not defined.	No	Yes	Histopathological confirmation of dysplasia or carcinoma	WL: 50 AF: 50 Tissue reflectance: 0	WL: 98 AF: 81 tissue reflectance: 86
12	Lalla et al. 2016 (Lalla et al., 2016)	Specialist oral medicine clinic	233	Patients presenting with white, red, mixed red-white lesions.	Yes	Yes	Identafi. LAF & negative diascopy positive for dysplasia or SCC	Yes	Yes	1. COE for confirmation of presence of OPMD 2. Histopathological confirmation of dysplasia	Clinical: WL: 100 Violet light: 27.5 Green-Amber light: 40 Histopathology: WL: 47.35 Violet light: 12.5 Green-Amber light: 37.3	Clinical: WL: 100% Violet light: 27.5% Green-Amber light: 40 Histopathology: WL: 87.5 Violet light: 85.4 Green-Amber light: 62.5

OFI as adjunctive tool to COE	13	Awan et al. 2011 (Awan et al., 2011)	Specialist oral medicine clinic	126	Patients presenting with white, red and mixed white/red patches.	Yes	No, incandescent operatory light	Veloscope. LAF considered positive for diseased tissue	No	Yes	COE used as gold standard to diagnose OPMD	AF alone: 87.1	AF alone: 21.4
	14	Canjau et al. 2018 (Cânjău et al., 2018)	Specialist oral surgery	18	No inclusion or exclusion criteria.	Yes	Unclear, overhead light used	VELscope. LAF considered positive for malignancy	Unclear	Yes	Histopathological confirmation of carcinoma only	AF alone: 94.44	AF alone: 100
	15	Chiang et al. 2018 (Chiang et al., 2018)	Specialist oral surgery	126	Patients with mucosal disorders and history of alcohol, tobacco and betel quid	Yes	Unclear	Autofluorescence digital photography. Unclear parameters	No	Yes	Histopathological confirmation of dysplasia or malignancy	AF alone: 77.94	AF alone: 35.42
	1	Bhatia et al. 2014 (Bhatia et al., 2014)	General dental practice	222	Patients presenting to a general dental clinic for general check-up	Yes	No. Incandescent operatory light	VELscope. LAF or negative diascopy considered positive for dysplasia/SCC. 2 week review protocol used for positive diascopy	Yes	Yes	1. A referral decision to oral medicine specialist 2. Histopathological diagnosis of biopsied lesions	COE alone: 44 AF alone: 64 Combined: 73.9	COE alone: 99 AF alone: 54.3 Combined: 97.9
	2	Jayaprakash et al. 2009 (Jayaprakash et al., 2009)	Specialist oral medicine	249	a) clinically suspicious oral lesions b) a history of treated OSCC c) recently diagnosed untreated OPMD or OSCCs	Yes	Yes	Fluorescence imaging and point spectroscopy. LAF considered positive for dysplasia or carcinoma	Unclear	Yes	Histopathological confirmation of dysplasia or carcinoma	All grades of OPMD & OSCC: WLE:52 AF alone:72 Combined:83	All grades of OPMD & OSCC: WLE:70 AF alone:50 Combined: 38
	3	Betz et al. 2002 (Betz et al., 2002)	Specialist otolaryngology	214	Patients with proven malignancy or clinically suspicious lesions of the oral cavity or oropharynx	Yes	Yes	Modified short xenon lamp for in vivo tissue excitation. Subjective darker shade of green considered positive for malignancy.	Unclear	Yes	Histopathological confirmation of carcinoma only	COE: 99.2 AF alone: 87.8 Combined: 100	COE: 42.9 AF alone: 56.4 Combined:51.3

4	Rana et al. 2012 (Rana et al., 2012)	Specialist oral surgery	COE group: N=166 COE+AF group: N= 123	Patients with oral premalignant lesions randomly allocated into two groups	YES	No. Overhead incandescent light	VELscope. LAF indicated dysplasia/malignancy. Negative diascopy also considered positive for dysplasia/malignancy.	Yes	Yes	Histopathological confirmation of dysplasia or carcinoma	COE: 17 Combined: 100	COE: 97 Combined:74
5	Hanken et al. 2013 (Hanken et al., 2013)	Specialist oral medicine clinic	120	Patients with suspicious oral premalignant lesions	Yes	Yes	VELscope LAF indicates underlying dysplasia/malignancy	Unclear	Yes	Histopathological confirmation of dysplasia or malignancy	COE: 5.9 Combined: 97.9	COE: 33.3 Combined: 41.7
6	Farah et al. 2012 (C.S Farah et al., 2012)	Specialist oral medicine clinic	118	Patients with an oral mucosal lesion (white, mixed white-red).	Yes	No. Incandescent operatory light	VELscope. LAF and negative diascopy was considered indicative for dysplasia/malignancy	Yes	Yes	Histopathological diagnosis for dysplasia on histopathology	COE: 25 AF alone: 30 Combined: 46	COE: 82 AF alone: 63 Combined: 68
7	Amirchaghmaghi et al. 2018 (Amirchaghmaghi et al., 2018)	Specialist oral medicine clinic	54	Patients presenting with soft tissue lesions needing incisional or excisional biopsies	Yes	No, Incandescent operatory light	VELscope. Regions with LAF or that seen as red/orange were considered suspicious	No	Yes	Histopathological confirmation of dysplasia or carcinoma	Dysplastic lesions only: COE: 75 AF alone: 83 Combined: 100 Dysplasia + SCC: COE: 81 AF alone: 90 Combined: 100 Oral Mucosal Lesions: COE: 86 AF alone: 90 Combined: 100	Dysplastic lesions only: COE: 71 AF alone: 12 Combined: 11 Dysplasia + SCC: COE: 67 AF alone: 12 Combined: 6 Oral Mucosal Lesions: COE: 85 AF alone: 15 Combined: 12

1	Mehrotra et al. 2010 (Mehrotra et al., 2010)	Specialist oral medicine clinic	100	Patients with the presence of clinically innocuous lesions	Yes	No. Overhead dental light	VELscope. LAF indicates dysplasia or carcinoma	No	Yes	Histopathological confirmation of dysplasia or carcinoma	AF alone: 50	AF alone: 38.9
2	Awan et al. 2015 (Awan et al., 2015)	Specialist oral medicine clinic	116	Consecutive sample of patients with white, red and mixed white and red patches	Yes	Unclear	VELscope. LAF indicates dysplasia	No	Yes	Histopathological confirmation of dysplasia	AF alone: 84.1	AF alone: 15.3
3	Jayaprakash et al. 2009 (Jayaprakash et al., 2009)	Specialist oral medicine clinic	249	a) clinically suspicious oral lesions b) a history of treated OSCC c) recently diagnosed untreated OPMD or OSCCs	Yes	Yes	Fluorescence imaging and point spectroscopy. LAF considered positive for dysplasia or carcinoma	Unclear	Yes	Histopathological confirmation of dysplasia or carcinoma	All grades of OPMD + OSCC: WLE:52 AF alone:72, Combined:83	All grades of OPMD + OSCC: WLE:70 AF alone:50 Combined: 38
4	Scheer et al. 2011 (Scheer et al., 2011)	Specialist oral and maxillofacial surgery	64	Patients referred to rule out invasive SCC	Yes	Not specified. Possible use of photos for diagnosis	VELscope. AF judgement based on photos. LAF considered positive for dysplasia/malignancy	Unclear	Yes	Histopathological confirmation of dysplasia or carcinoma	AF alone: 100	AF alone: 80.8
5	Betz et al. 2002 (Betz et al., 2002)	Specialist otolaryngology	214	Proven malignancy or clinically suspicious lesions of the oral cavity or oropharynx	Yes	Yes	Modified short xenon lamp for in vivo tissue excitation Subjective darker shade of green considered positive for malignancy.	Unclear	Yes	Histopathological confirmation of carcinoma only	COE: 99.2 AF alone: 87.8 Combined: 100	COE: 42.9, AF alone: 56.4 Combined:51.3
6	Rana et al. 2012 (Rana et al., 2012)	Specialist oral surgery	COE group: N=166 COE+AF group: N= 123	Only patients with oral premalignant lesions randomly allocated into two groups	YES	No. Overhead incandescent light	VELscope. LAF indicated dysplasia/malignancy. Negative diascopy also considered positive for dysplasia/malignancy.	Yes	Yes	Histopathological confirmation of dysplasia or carcinoma	COE: 17 Combined: 100	COE: 97 Combined:74
7	Hanken et al. 2013 (Hanken et al., 2013)	Specialist oral medicine clinic	120	Patients with suspicious oral premalignant lesions	Yes	Yes	VELscope. LAF indicates underlying dysplasia/malignancy	Unclear	Yes	Histopathological confirmation of dysplasia or malignancy	COE: 5.9 Combined: 97.9	COE: 33.3 Combined: 41.7

8	Koch et al. 2011 (Koch et al., 2011)	Specialist oral surgery	78	Patients with clinically diagnosed SCC or suspicious mucosal lesions	Yes	Yes. Diagnosis based on photographs	VELscope. Characteristics of AF determined from photographs. A low or absent AF signal, as well as red AF signal was considered positive for dysplasia or SCC.	Unclear	Yes	Histopathological confirmation of carcinoma only	COE: 96.6 AF alone: LAF parameter only: 93 Red AF only: 20	COE: 95.8 AF alone: LAF parameter only: 15 Red AF only: 98
9	Paderni et al. 2011 (Paderni et al., 2011)	Specialist oral medicine	175	Patients with at least one oral mucosal lesion with clinical suspicion of OPMD or OSCC	Yes	Yes.	VELscope. Abnormally dark on fluorescence in the body or boundary of lesion was considered positive for dysplasia or malignancy.	Yes	Yes	Histopathological confirmation of dysplasia or carcinoma	AF alone: Lesions with dysplasia vs lesions w/o dysplasia: 65.5 (sig) Lesions with mild dysplasia vs lesions w/o dysplasia: 60 (sig) Lesions with moderate/severe dysplasia vs lesions without dysplasia: 71.4 (sig) High risk lesions vs low risk lesions: 75 (sig)	AF alone: Lesions with dysplasia vs lesions w/o dysplasia: 97.4 (sig) Lesions with mild dysplasia vs lesions w/o dysplasia: 97.4 (sig) Lesions with moderate/severe dysplasia vs lesions without dysplasia: 97.4 (sig) high risk lesions vs low risk lesions: 92.3 (sig)
10	Farah et al. 2012 (C.S Farah et al., 2012)	Specialist oral medicine clinic	118	Patients with an oral mucosal lesion (white, mixed white-red).	Yes	No. Incandescent operatory light	VELscope. LAF and negative diascopy was considered indicative for dysplasia/malignancy	Yes	Yes	Histopathological diagnosis of dysplasia on histopathology	COE: 25 AF alone: 30 Combined: 46	COE: 82 AF alone: 63 Combined: 68
11	Petruzzi et al. 2014 (Petruzzi et al., 2014)	Specialist oral medicine clinic	56	Patients with oral lesions suspicious for malignancy and who had a history of oral lesions or were at high risk for an oral lesion	Yes	No. Incandescent operatory light	VELscope. LAF was considered positive for dysplasia or malignancy	No	Yes	Histopathological diagnosis of dysplasia or carcinoma	AF alone: detection of dysplasia + malignancy: 70 AF alone: detection of moderate/severe OED/SCC (mild dysplasia considered negative): 76.47	AF alone: detection of dysplasia + malignancy: 57.69 AF alone: detection of moderate/severe OED/SCC (mild dysplasia considered negative): 51.28

12	Marzouki et al. 2012 (Marzouki et al., 2012)	Specialist head and neck oncology clinic	33	Patients with high smoking and alcohol history, with suspicious lesion, or patients with history of treated oral cancer on review for recurrence or second primary	Yes	Unclear	VELscope. LAF was deemed positive for dysplasia or carcinoma	No	Yes	Histopathological confirmation of dysplasia or carcinoma	COE: 61.5 AF alone: 92	COE: 87.5 AF alone: 77
13	Lalla et al. 2016 (Lalla et al., 2016)	Specialist oral medicine clinic	233	Patients presenting with white, red, mixed red-white lesions.	Yes	Yes	Identafi. LAF & partial blanching positive for dysplasia or malignancy	Yes	Yes	1. COE for confirmation of presence of OPMD 2. Histopathological confirmation of dysplasia	Clinical: WL: 100 Violet light: 27.5 Green-Amber light: 40 Histopathology: WL: 47.35 Violet light: 12.5 Green-Amber light: 37.3	Clinical: WL: 100 Violet light: 27.5 Green-Amber light: 40 Histopathology: WL: 87.5 Violet light: 85.4 Green-Amber light: 62.5
14	Moro et al. 2010 (Moro et al., 2010)	Specialist oral medicine clinic	32	Patients with a history of oral cancer, presence of OPMD or suspicious lesion.	Yes	Unclear	Prototype. LED lamp emitting 450nm. No defined parameters	No	Yes	Histopathological confirmation of dysplasia or carcinoma	AF alone: 100	AF alone: 93
15	Amirchaghmaghi et al. 2018 (Amirchaghmaghi et al., 2018)	Specialist oral medicine clinic	54	Patients presenting with soft tissue lesions needing incisional or excisional biopsies	Yes	No, Incandescent operatory light	VELscope. Regions with LAF or that seen as red/orange were considered suspicious	No	Yes	Histopathological confirmation of dysplasia or carcinoma	Dysplastic lesions only: COE: 75 AF alone: 83 Combined: 100 Dysplasia + SCC: COE: 81 AF alone: 90 Combined: 100 Oral Mucosal Lesions: COE: 86 AF alone: 90 Combined: 100	Dysplastic lesions only: COE: 71 AF alone: 12 Combined: 11 Dysplasia + SCC: COE: 67 AF alone: 12 Combined: 6 Oral Mucosal Lesions: COE: 85 AF alone: 15 Combined: 12

16	Awan et al. 2011 (Awan et al., 2011)	Specialist oral medicine clinic	126	Patients presenting with white, red and mixed white/red patches.	Yes	No, incandescent operatory light	VELscope. LAF considered positive for diseased tissue, no mention if it indicates dysplasia or malignancy	No	Yes	COE used as gold standard to diagnose OPMD	AF alone: 87.1	AF alone: 21.4
17	Simonata et al. 2016 (Simonato et al., 2017)	Screening clinic, OFI device used by dental student and specialist in oral medicine	5	Prospective, random selection from patients in screening clinic.	Yes	Yes	Evince. LAF considered positive for malignancy or dysplasia	Unclear	Yes	COE used as gold standard to diagnose OPMD Histopathological confirmation of dysplasia or carcinoma	Unskilled in detection of OED: COE: 50 AF alone: 100 Skilled clinician in detection of OED COE: 100 AF alone: 100	Unskilled in detection OED: COE: 46.15 AF alone: 46.15 Skilled clinician in detection of OED: COE: 38 AF alone: 46
18	Babiuch et al. 2012 (Babiuch et al., 2012)	Specialist Oral Surgery clinic	18	Patients with history of lip and oral cavity cancer enrolled	Yes	No, incandescent operatory light	VELscope. LAF considered positive for malignancy	Unclear	Yes	Histopathological confirmation of dysplasia or malignancy	AF alone: 100	AF alone: 12.5
19	Chiang et al. 2018 (Chiang et al., 2018)	Specialist oral surgery	126	Patients with mucosal disorders and history of alcohol, tobacco and betel quid	Yes	Unclear	Autofluorescence digital photography. Unclear parameters	No	Yes	Histopathological confirmation of dysplasia or malignancy	AF alone: 88.89	AF alone: 43.86
20	Sawan et al. 2015 (Sawan & Mashlah, 2015)	Specialist centre	71	No inclusion or exclusion criteria.	Unclear	Unclear	VELscope. Positive measures not defined.	No	Yes	Histopathological diagnosis of carcinoma only	AF alone: 100	AF alone: 74.14
21	Lane et al. 2006 (Lane et al., 2006)	Specialist oral medicine clinic	50	Patients with history of biopsy confirmed oral dysplasia or SCC	Yes	Yes	Cone of blue excitation light emitted from handheld unit prototype LAF positive for abnormality	No	Yes	Histopathological diagnosis of dysplasia or carcinoma	AF alone: 98	AF alone: 100

**Table 2: Autofluorescence imaging in visualisation of oral mucosal lesions**

Autofluorescence in visualisation of oral mucosal lesions	No	Author, Publication Year	General or Specialist Setting	Sample Size	Population Type Assessed	COE done prior to AF?	Was WL used	AF device and technique	Was diascopy used	Clinical lesions detected	Lesions detected by AF device	Border Distinctness	Lesion Visibility
	1	Bhatia et al. 2014 (Bhatia et al., 2014)	General dental practice	222	Patients presenting to a general dental clinic for general check-up	Yes	No. Incandescent operatory light	VELscope. LAF or negative diascopy considered positive for dysplasia/SCC. 2 week review protocol used for positive diascopy	Yes	161	222 Additional 61 lesions were discovered using VELscope. 58 of which displayed LAF. Lesion detection enhanced by 20%.	Border distinctness increased in 21 lesions with VELscope (13%), while COE provided greater border distinctness in 7 (4.3%)	VELscope increased visibility of 16 (9.9%) of lesions detected with COE while 7 (4.3%) were more visible under COE.
	2	Jayaprakash et al. 2009 (Jayaprakash et al., 2009)	Specialist oral medicine clinic	249	a) clinically suspicious oral lesions b) a history of treated OSCC c) recently diagnosed untreated OPMD or OSCCs	Yes	Yes	Fluorescence imaging and point spectroscopy. LAF considered positive for dysplasia or carcinoma	Unclear	249	325 Additional 76 suspicious lesions identified after WLE with AF and underwent biopsy	Not recorded	Not recorded



3	Betz et al. 2002 (Betz et al., 2002)	Specialist otolaryngology	214	Patients with proven malignancy or clinically suspicious lesions of the oral cavity or oropharynx	Yes	Yes	Modified short xenon lamp for in vivo tissue excitation. Subjective darker shade of green considered positive for malignancy.	Unclear	214	AF alone: 137 Combined: 199	Subjective Border demarcation of SCC cases: COE: Poor: 8.9%, Sufficient: 54.7% Good: 36.7% AF alone: Poor: 37.5% Sufficient: 30.4% Good: 32.1% Combined: Poor: 10.3% Sufficient: 26.5% Good: 63.2%	Not recorded
4	Paderni et al. 2011 (Paderni et al., 2011)	Specialist oral medicine clinic	175	Patients with at least one oral mucosal lesion with clinical suspicion of OPMD or OSCC	Yes	Yes.	VELscope. Abnormally dark on fluorescence in the body or boundary of lesion was considered positive for dysplasia or malignancy.	Yes	175	175	18.4% of lesions noted slight improvement while 66% noted marked improvement, 32.7% decreased distinction with VELscope	49% slight improvement, 28.6% decreased improvement in lesion visibility with VELscope
5	Farah et al. 2012 (C.S Farah et al., 2012)	Specialist oral medicine clinic	118	Patients with an oral mucosal lesion (white, mixed white-red).	Yes	No. Incandescent operatory light	VELscope. LAF and negative diascopy was considered indicative for dysplasia/malignancy	Yes	113	118 Additional 5 lesions detected with VELscope	No significant difference between border distinctness	No significant difference between visibility

6	Marzouki et al. 2012 (Marzouki et al., 2012)	Specialist head and neck oncology clinic	33	Patients with high smoking and alcohol history, with suspicious lesion, history of treated oral cancer	Yes	Unclear	VELscope. LAF was deemed positive for dysplasia or carcinoma	No	17	33 16 additional suspicious lesions were detected with VELscope. Lesion detection enhanced by 31%	Not recorded	Not recorded
7	Lalla et al. 2016 (Lalla et al., 2016)	Specialist oral medicine clinic	233	Patients presenting with white, red, mixed red-white lesions.	Yes	Yes	Identafi. LAF & partial blanching positive for dysplasia or malignancy	Yes	231	233 Additional 2 lesions detected by Identafi	Not recorded	Identafi's WL was equivalent to WL used with use of overhead LED & magnification
8	Lalla et al. 2015 (Lalla et al., 2015)	General dental clinic	161	Patients presenting for general dental check	Yes	No. Incandescent operatory light	Identafi. LAF & partial blanching positive for dysplasia or malignancy	Yes	161	161	COE = 30.1% WL = 42.6% Violet light = 55.9% Green-amber = N/A	COE= 75% WL = 84.5% Violet = 77.9% Green-amber = N/A